

# Boys Will Be Boys

Research by and for adolescent males of all ages and sexes

compiled by Katherine Lee, AIR staff

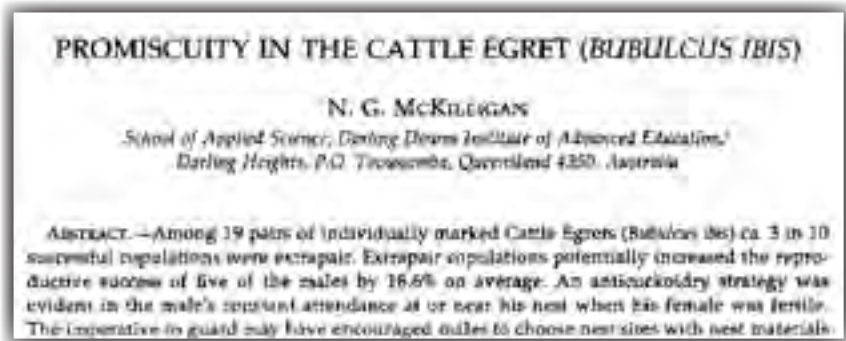


## Egrets: I've Had a Few

"Promiscuity in the Cattle Egret (*Bubulcus ibis*)," N.G. McKilligan, *Auk*, vol. 107, no. 2, April 1990, pp. 334-41.

## Tight Wad

"A Case of Foreign Body in the Urinary Bladder -- Chewing Gum Found in Urinary Bladder" [article in Japanese], K. Shigemura, K. Yuen, N. Kataoka and T. Iwamoto, *Hinyokika Kiyo*, vol. 48, no. 4, April 2002, pp. 229-30. (Thanks to N.E. Savard for bringing this to our attention.) The authors are at Nishiwaki Municipal Hospital, Japan.



## A Long Story

"Are Long Penis Bones an Adaption to High Latitude Snowy Environments?" Steven H. Ferguson and Serge Larivière, *Oikos*, vol. 105, no. 2, May 2004, pp. 255-67. (Thanks to Renate Wesselingh for bringing this to our attention.)

## Togetherhness

"Reverse Mounting During the Courtship of the European Shag *Phalacrocorax-Aristotelis*," J. Ortegarruano and J.A. Graves, *Condor*, vol. 93, no. 4, November 1991, pp. 859-63. (Thanks to Ig Nobel Prize winner Charles Paxton for bringing this to our attention.)

## Peculiar Events in the Armadillo

"Absence of Penile Erections During Paradoxical Sleep -- Peculiar Penile Events During Wakefulness and Slow Wave Sleep in the Armadillo," Jorge M. Affanni, Claudio O. Cervino, and Hernan J. Aldana Marcos, *Journal of Sleep Research*, vol. 10, 2001, pp. 219-28. (Thanks to Gary Bass for bringing this to our attention.)

The authors, who are at Universidad de Buenos Aires, Buenos Aires, Argentina, and Universidad de Moron, Argentina, include a number of instructive photographs of the peculiar events, and observe that:

This animal has a very long penis, which exhibits remarkable phenomena during wakefulness (W), slow wave sleep (SWS) and paradoxical sleep (PS). During W it remains retracted within a skin receptacle. During SWS penile protrusion can be observed together with very complex movements. Protrusion is a non-erectile event during which the penis remains out of its receptacle but without rigidity.

